Late Winter 2020

BURLINGTON EMERGENCY & VETERINARY SPECIALISTS

SERVICE SPOTLIGHT

DIAGNOSTIC IMAGING

A Timely, Accurate Diagnosis is Critical For Proper Treatment Planning.

That's why we have invested in a full range of leading-edge diagnostic equipment for our state-of-the-art facility. As Vermont's only specialty and 24/7 emergency animal hospital, we are proud to provide our primary care veterinary community with convenient access to the most advanced diagnostic resources in the state. This means that patients and their families no longer need to travel hours away for images to be captured and interpreted by board-certified specialists. When referring patients to BEVS, rest assured they will receive the most thorough, thoughtful, and timely care available locally.

24/7/365 Emergency and Critical Care • Acupuncture • Dentistry • Diagnostic Imaging
Internal Medicine • Oncology • Radioiodine • Rehabilitation • Surgery

802.863.2387 | bevsvt.com

Diagnostic Imaging Modalities Available at BEVS

We are committed to providing the highest level of diagnostic service and expertise in the region. In fact, all of our images are interpreted by ACVR or ACVIM diplomates to ensure accuracy.

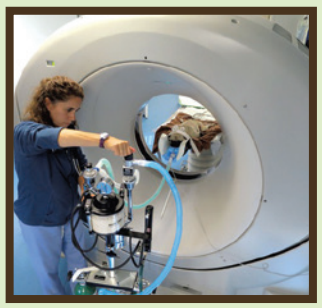

Computed Tomography (CT): In BEVS' oncology cases, CT is immeasurably valuable for assessing local and distant disease, as well as providing a substantial amount of information about deep tumors (pulmonary, cardiac, vascular, and visceral). It's important to note our CT technology is multi-slice with a gantry large enough to accommodate a giant breed canine's chest, which allows us to perform images on even the largest of dog breeds. For general surgical planning, CT can be invaluable in determining the proper approach to maximize outcomes and minimize complications.

Turnaround: Interpreted by a Radiologist (ACVR) within 3-6 hours

Digital Radiograph (x-rays): Referring DVMs can expect the very best in image quality from BEVS. Our state-of-the art equipment allows adjustment of brightness, contrast, zoom, and pan to optimize both bone and soft tissue in one exposure.

Turnaround: Interpreted by a Radiologist (ACVR) within 1-2 hours

Echocardiography: Our echocardiography equipment employs color flow and contrast studies to provide a fast and accurate diagnosis when it comes to almost all heart conditions.

Turnaround: Interpreted by an Internist (SAIM)

Endoscopy: We offer veterinarians and their patients a number of endoscopic procedures. Our experts are able to examine inside surfaces of hollow organs, find and extract foreign bodies, and collect biopsy samples of tumors or other lesions. We perform bronchoscopy, colonoscopy, cystoscopy, laparoscopy, rhinoscopy, and thoracoscopy.

Turnaround: Interpreted by an Internist (SAIM) immediately

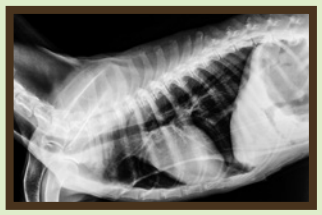

Fluoroscopy: This special form of x-ray imaging, often referred to as an "x-ray movie," allows our specialists to see movement of body structures. We commonly use this form of imaging to examine bone instability, collapsing trachea, swallowing disorders, and urinary tract issues.

Turnaround: Interpreted by a Radiologist (ACVR) within 1-2 hours

Magnetic Resonance Imaging (MRI): Our MRI is a 1.5 tesla magnet which enables us to run shorter scan times, reduce possible motion distortion, create higher quality images, and interpret the scans within hours. MRI technology at BEVS also allows our team to perform a cerebrospinal fluid (CSF) tap, if necessary, on seizure patients and suspected intervertebral disc disease (IVDD) dogs.

Turnaround: Interpreted by a Radiologist (ACVR) within 3-6 hours

Ultrasonography: Also available as an outpatient diagnostic service, ultrasounds are often the preferred method for imaging soft tissue and internal organs in a non-anesthetized patient. Safe, reliable, and relatively inexpensive, it is a great way to observe abnormalities deeper in the body.

Turnaround: Interpreted by an Internist (SAIM) immediately

CT or MRI?

Imaging makes diagnosing a patient's condition easier and faster, but it can sometimes be difficult or confusing to decide when or why computed tomography (CT) is preferred over magnetic resonance imaging (MRI), and vice versa. Both are cross-sectional imaging modalities that provide images of slices of the patient, however, as a general rule, bone and lung details are much better with CT, while soft tissue contrast is much better with MRI. The experts at BEVS follow these guidelines:

CT: Specific veterinary medicine uses:

- Lung and nasal passage evaluation, emergency imaging, stroke, hemorrhage, elbow dysplasia, fragmented coronoid process, advanced thoracic and abdominal diseases
- Used more often to evaluate structures that have high contrast differences (lungs), are dense (bones), and for acute hemorrhage
- Can be performed under heavy sedation, making it an ideal option for patients who are not general anesthesia candidates
- Costs less than MRI
- Faster than an MRI

MRI: Specific veterinary medicine uses:

- Cervical spinal cord evaluation, caudal brain and brainstem lesions, peripheral nerve sheath tumors, seizures, shoulder issues, muscle tears and strains, cranial cruciate ruptures
- Used more often to evaluate soft tissues, lesions, inflammatory and degenerative diseases, in minimally contrasting regions
- Differentiates grey matter, white matter, nerves, and cerebrospinal fluid (CSF) to a much greater extent than CT
- Requires anesthesia
- Costs more than CT and slower than CT

Case Study: Using CT and MRI to Help Diagnose Luna's Pain



Luna, an 11y FS Border Collie Mix, presented May 30, 2019, for pain associated with her head and right ear. She had had a dental prophylaxis in March 2019, and the pcDVM noted a ruptured tympanum at that time on the right side. She was treated with topical enrofloxacin and oral prednisone 10mg once daily.

On physical exam, she was somewhat anxious and resisted cervical manipulation, but there were no other significant findings. Blood work was unremarkable, aside from a mild elevation in alkaline phosphatase thought to be due to the prednisone. We elected to proceed with a CT scan of her head and cervical region to assess the tympanic bulla and rule out cervical IVDD (see Figures 1 and 2).

Findings: There is a hypodense mass with uniform contrast enhancement at the dorsal cerebellum on midline. This mass measures 1.6 cm in diameter and has a broad base adjacent to the bone surface. Cerebellar herniation is not detected.

Conclusion: The cerebellar mass is likely extra-axial, with primary differential of meningioma. Intra-axial mass/neoplasia (glioma, astrocytoma, etc.) cannot be excluded.

Referral to a neurologist/neurosurgeon at Guardian Veterinary Specialists for surgical removal was recommended.

On June 13, 2019, Luna was assessed by the neurologist as having a normal physical exam. Abdominal ultrasound and thoracic radiographs were within normal limits, and a surgery was performed. A suboccipital bilateral craniectomy was performed, and a discolored mass completely removed and submitted for histopathology. Recovery from surgery was routine, and on June 15, 2019, Luna was released to the owners and sent home on prednisone 10mg q 12h orally.

Histopath revealed a transitional meningioma, grade 1, that was considered locally invasive, but thought to have a low metastatic rate. Luna did well and returned to normal activity over the summer until presenting again, October 24, 2019, with acute pain on cervical flexion. She had been treated with gabapentin 100mg q 12h and methocarbamol 500mg q 12h without improvement. Her physical exam was again relatively normal, with the exception of resenting cervical flexion. The owners elected to pursue an MRI of the head and neck, given Luna's history (see Figures 3 and 4).

Findings: There is a mass identified in the dorsal aspect of the caudal cerebellum that is broad-based along the dorsal and caudal margin. The mass demonstrates moderate, mildly heterogeneous contrast enhancement. The margins of the mass are mildly irregular. The mass measures approximately 2.2 cm in width, 1.7 cm in height, and 1.7 cm in length. The mass is hyperintense and heterogeneous on T2-weighted and FLAIR images. The mass is iso- to hypointense and heterogeneous on T1-weighted images without contrast. There are ill-defined regions of hyperintensity on FLAIR and T2-weighted images that extend beyond the regions of contrast enhancement associated with the mass.

Conclusion: There is an extra-axial cerebellar mass as described. Consideration should be given to regrowth of the reported meningioma. Lesser consideration is given to a granuloma or other types of neoplasia.

On November 21, 2019, Luna was referred for stereotactic radiation therapy to Angel Animal Medical Center. She had been treated with prednisone 10mg/day, gabapentin 200mg q 6h, and hydroxyurea 500mg every other day. A planning CT was performed, and repeat thoracic radiographs and ultrasound were normal. Stereotactic radiation therapy was delivered in three fractions over November 25–27, 2019. Luna was discharged to the owner and is asymptomatic on the gabapentin and prednisone. The expected average survival time following radiation therapy ranges from 1.5 to 2 years.

Luna's presentation was unusual for a meningioma with the primary complaint being cervical pain. One explanation may be the location of the lesion, causing compression of the caudal cerebellum.

Takeaway: While both imaging modalities were utilized for Luna, MRI is preferred for imaging the brain and the spinal cord. BEVS has a state-of-the-art 1.5 Tesla MRI that allows us to acquire superior images to those from lower-strength magnets, while doing so with shorter scan times. Patients that would benefit from MRI include seizures with onset greater than six years of age, or seizures that are not responding to reasonable AED therapy suspected IVDD, FCE, or inflammatory CNS disease, lumbosacral stenosis, nasal disease, and many more.

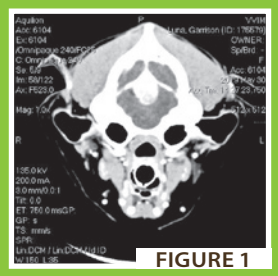

FIGURE 1

FIGURE 2

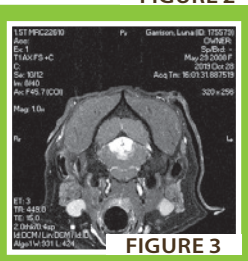

FIGURE 3

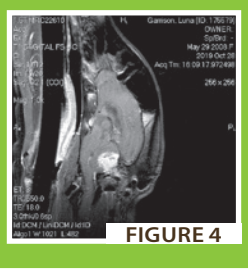

FIGURE 4

We're rolling out the Welcome Mat!

Would you like a behind-the-scenes tour of our hospital? Call us at (802) 863-BEVS to schedule your personal visit to see:

- 18, 000 square feet
- Three surgery suites
- Dental suite with advanced imaging
- 12 consultation rooms
- Special procedure room
- Intensive care unit
- Radioiodine ward
- Comfort room
- Chemotherapy suite
- Isolation ward
- 4-slice CT scanner
- 1.5 T MRI
- Rehabilitation services with underwater treadmill
- 60+ dedicated team members

SERVICE SPOTLIGHT

Late Winter 2020

DIAGNOSTIC IMAGING

BURLINGTON EMERGENCY & VETERINARY SPECIALISTS

1417 Marshall Avenue • Williston, VT 05495

Referring Patients and Clients to BEVS

We appreciate the opportunity to partner with you in the care of your patients. As a referral practice, our aim is to complement your practice by providing advanced diagnostics, specialty services, and 24/7 emergency care when you and your clients need us, all while staying close to home. To help expedite the referral process, please visit our website at bevsvt.com to access our "Patient Referral Portal." For your convenience, you can either complete and submit the form online or fax it to us at (802) 863-2348. If you have any questions, or would like to discuss imaging capabilities with one of our specialists, please call us at (802) 863-BEVS (2387). We're here to help in whatever way we can.